

Surgical Anatomy of the Lumbar Plexus: A Comprehensive Guide

The lumbar plexus is a complex network of nerves that originates from the spinal cord and innervates the lower extremities. Understanding its surgical anatomy is crucial for successful surgical interventions involving the pelvis, abdomen, and lower limbs.

Anatomical Landmarks

- **Psoas Major Muscle:** Forms the floor of the lumbar plexus, separating it from the abdominal cavity.
- **Quadratus Lumborum Muscle:** Forms the posterior boundary, located behind the lumbar plexus.
- **Intervertebral Foramina:** Sites where the nerve roots of the lumbar plexus exit the spinal canal.
- **Aorta:** Lies anterior to the lumbar plexus, supplying blood to the lower extremities.
- **Inferior Vena Cava:** Located to the right of the lumbar plexus, carrying deoxygenated blood back to the heart.

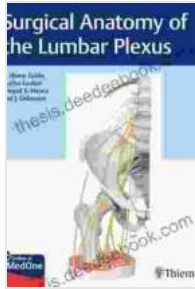Nerve Roots and Trunks

The lumbar plexus is formed by the ventral rami of spinal nerve roots L1-L4, which combine to form three main trunks:

Surgical Anatomy of the Lumbar Plexus by R. Shane Tubbs

★★★★★ 5 out of 5

Language : English



File size : 16907 KB
Text-to-Speech : Enabled
Screen Reader : Supported
Enhanced typesetting : Enabled
Print length : 523 pages



- **Upper Trunk:** Formed by L1.
- **Middle Trunk:** Formed by L2-L3.
- **Lower Trunk:** Formed by L4.

Divisions

Each trunk further divides into anterior and posterior divisions:

- **Anterior Divisions:** Emerge from the medial side of the trunks and form the femoral nerve, obturator nerve, and part of the lumbosacral trunk.
- **Posterior Divisions:** Emerge from the lateral side of the trunks and form the gluteal superior and inferior nerves, along with part of the lumbosacral trunk.

Branches

The lumbar plexus gives rise to numerous branches that innervate the lower limbs:

- **Femoral Nerve:** Provides sensation and motor function to the anterior thigh and leg.
- **Obturator Nerve:** Innervates the adductor muscles of the thigh and contributes to hip joint innervation.
- **Gluteal Nerves:** Supply the gluteal muscles, responsible for hip extension and abduction.
- **Lumbosacral Trunk:** Joins with the sacral plexus to form the sciatic nerve, innervating the posterior thigh and leg.

Surgical Significance

- **Abdominal and Pelvic Surgery:** Retraction of the lumbar plexus may be necessary for access during surgeries involving the aorta, inferior vena cava, or pelvic organs.
- **Lower Limb Surgery:** Injury to the lumbar plexus can occur during hip or knee replacements, necessitating careful dissection and nerve preservation.
- **Pain Management:** Targeted nerve blocks of the lumbar plexus can provide pain relief in conditions such as peripheral neuropathy or chronic pain syndromes.

Variations

Variations in the anatomy of the lumbar plexus are common and include:

- **Sacral Plexus Contribution:** The L4 or L5 nerve root may contribute to the formation of the sacral plexus.

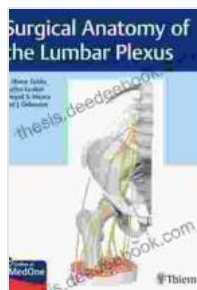- **Additional Trunks:** An accessory trunk may be present, formed by the division of the upper trunk.
- **Fusion of Trunks:** The upper and middle trunks may fuse to form a single trunk.

Clinical Implications

Understanding the surgical anatomy of the lumbar plexus is essential for:

- Avoiding nerve damage during surgical procedures.
- Targeting neural structures for pain management.
- Interpreting diagnostic imaging studies that involve the lumbar plexus.

The surgical anatomy of the lumbar plexus is a complex and intricate network. By understanding its anatomical landmarks, variations, and clinical significance, surgeons can perform interventions safely and effectively, while also managing any associated neurological complications.



Surgical Anatomy of the Lumbar Plexus by R. Shane Tubbs


★★★★★ 5 out of 5

Language	: English
File size	: 16907 KB
Text-to-Speech	: Enabled
Screen Reader	: Supported
Enhanced typesetting	: Enabled
Print length	: 523 pages

FREE

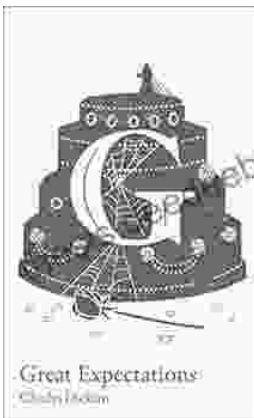
DOWNLOAD E-BOOK





The ABC of ABC Limericks: A Comprehensive Guide to the Quintessential Verse Form

: A Journey into the World of Limericks Welcome to the whimsical and witty world of ABC limericks, a beloved form of verse that...



GCSE Set Text Student Edition: Collins Classroom Classics - A Comprehensive Review

The GCSE Set Text Student Edition: Collins Classroom Classics is a meticulously crafted resource designed to support students in their GCSE English Literature studies....